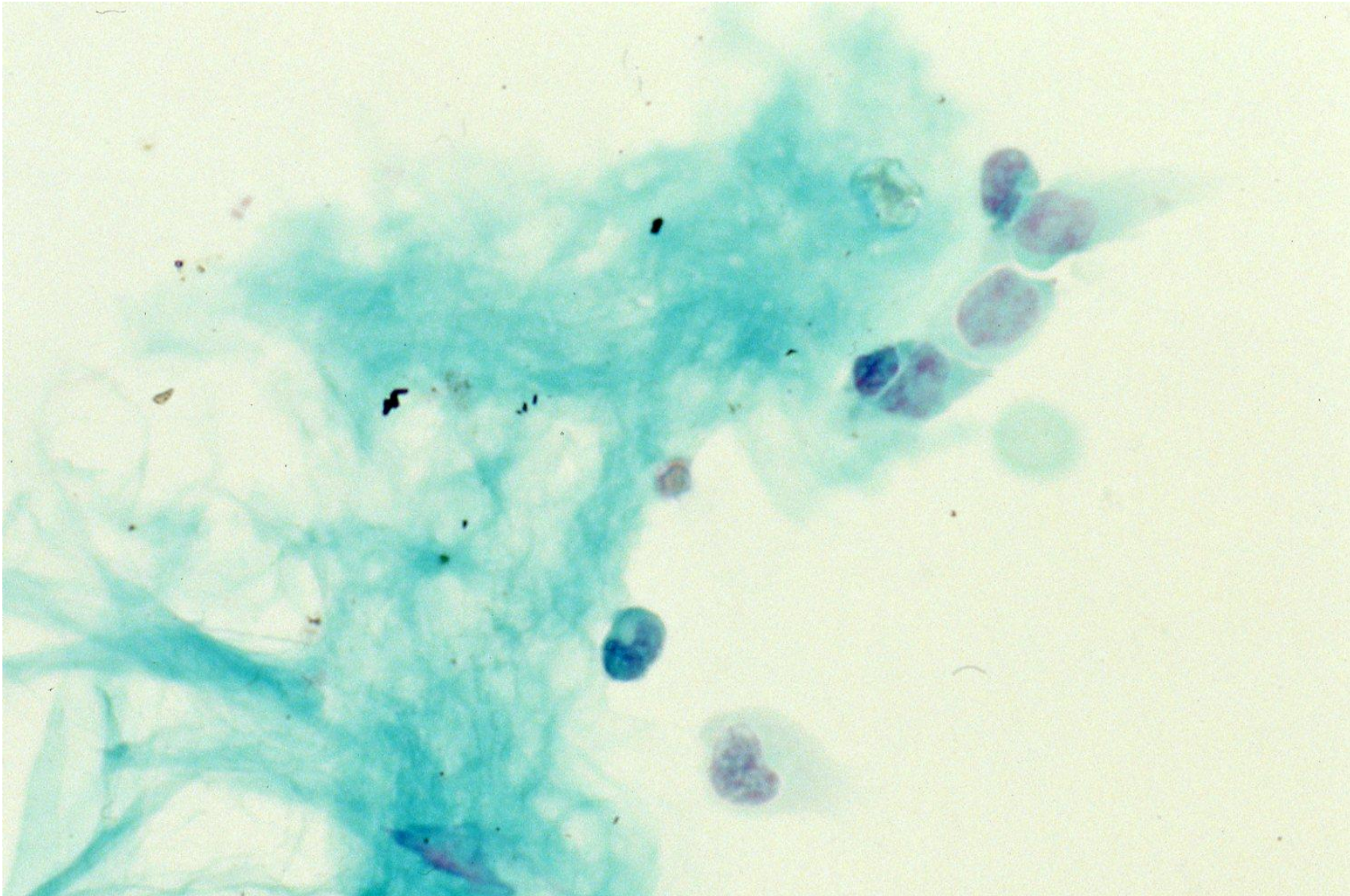


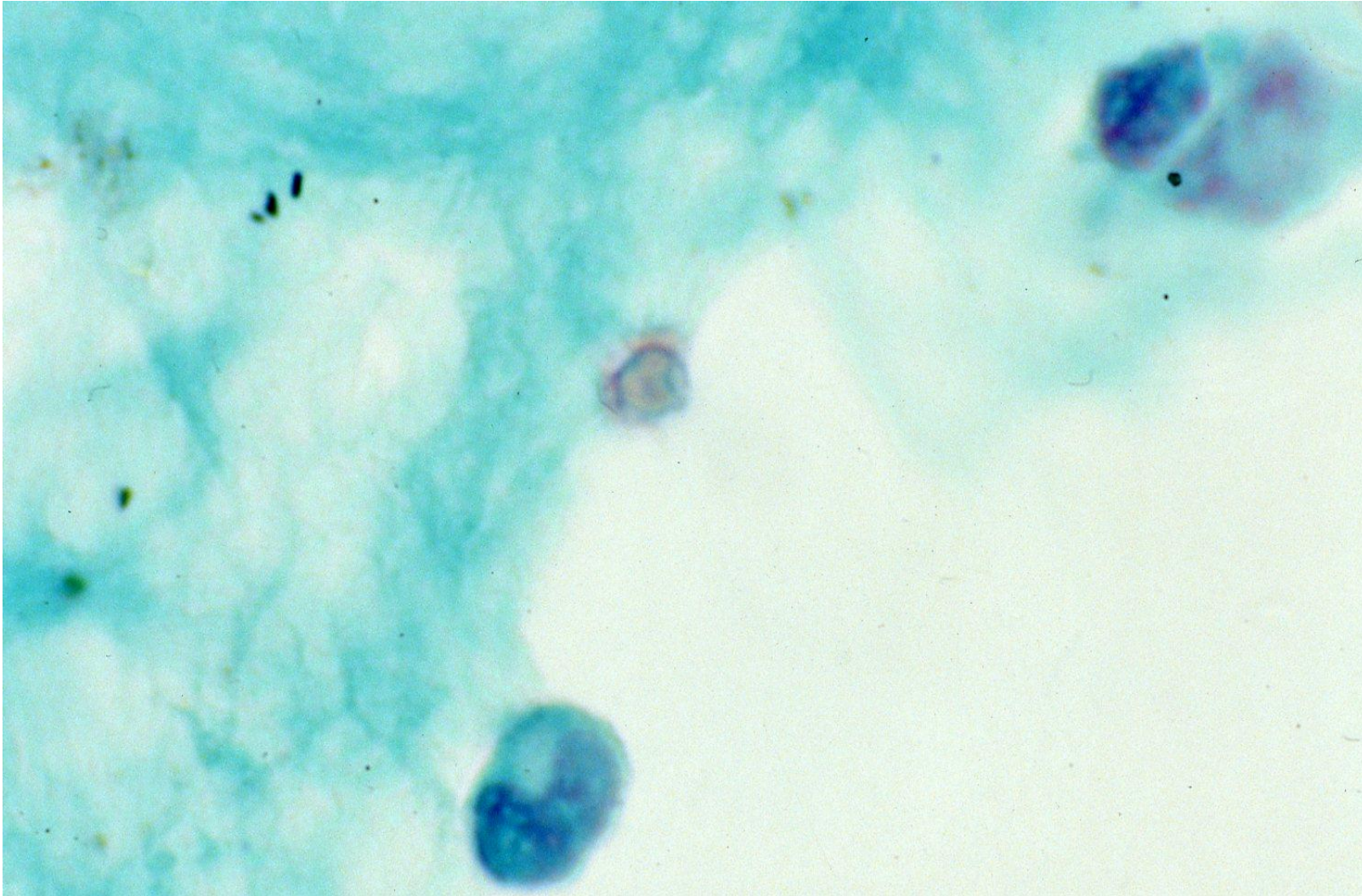
Cryptococcal meningitis (cerebrospinal fluid)

Cryptococcus neoformans occasionally involved meninges to cause cryptococcal meningitis, usually disseminated from a lung lesion.

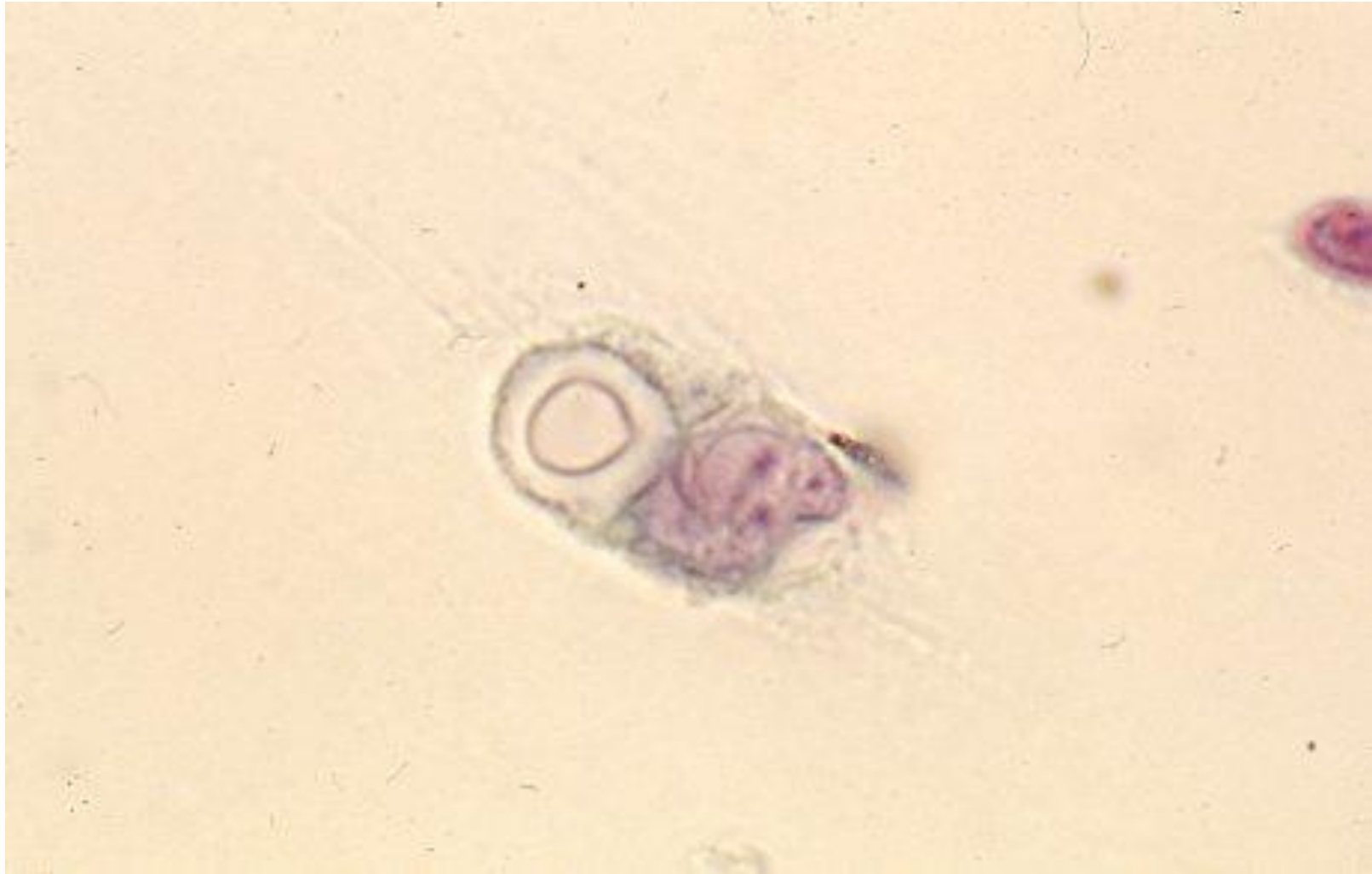Immunocompromised hosts, particularly AIDS patients, are susceptible to the pathogen. Cytological examination of the cerebrospinal fluid can identify yeasts with thin walls and thick sugar capsules (composed of glucuronoxylomannan). However, the yeasts in the specimen are small in number.



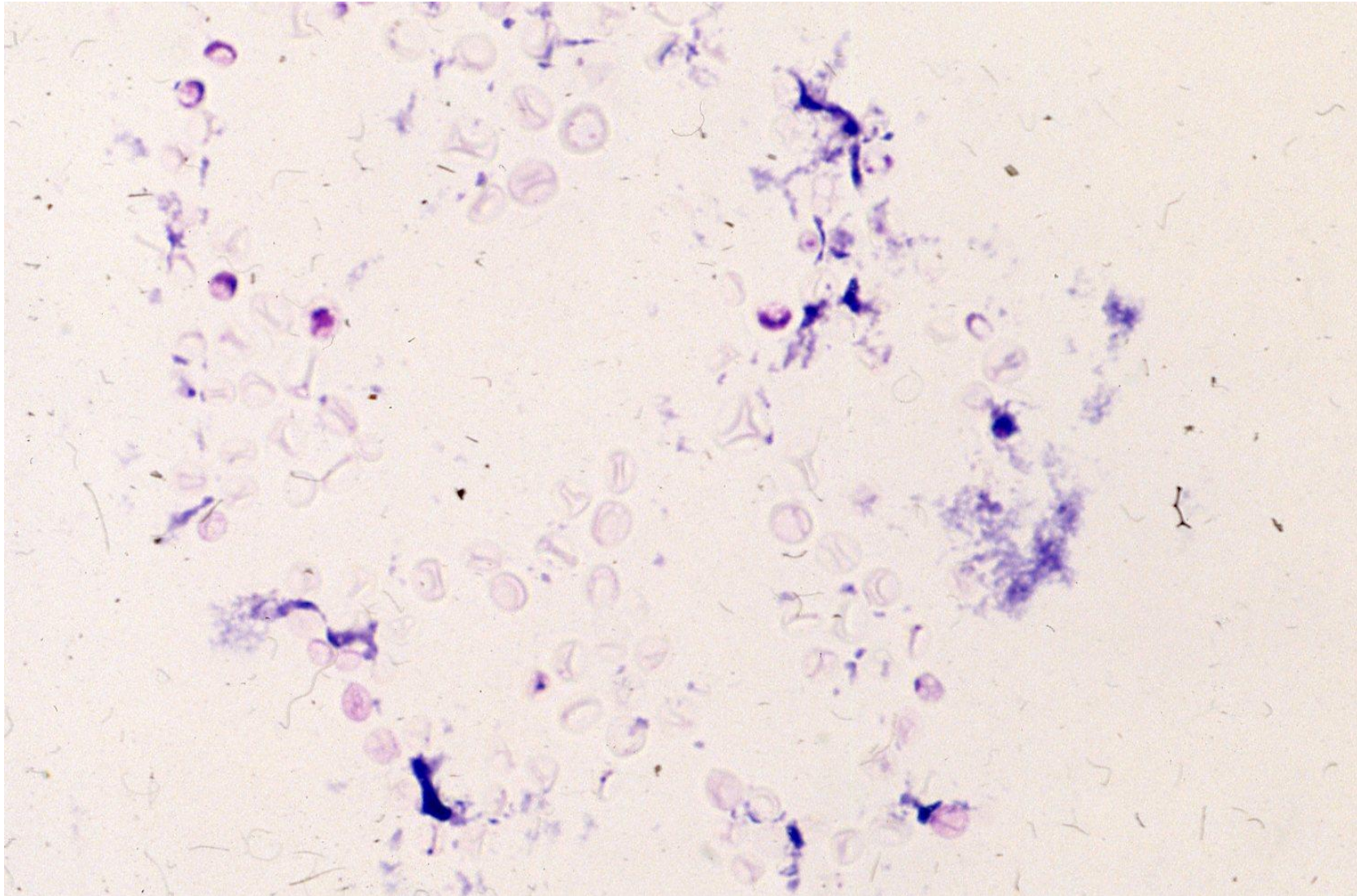
Papanicolaou-stained CSF cytology for cryptococcal meningitis.
A single yeast attaches onto the meningotheelial cell. Pap-1



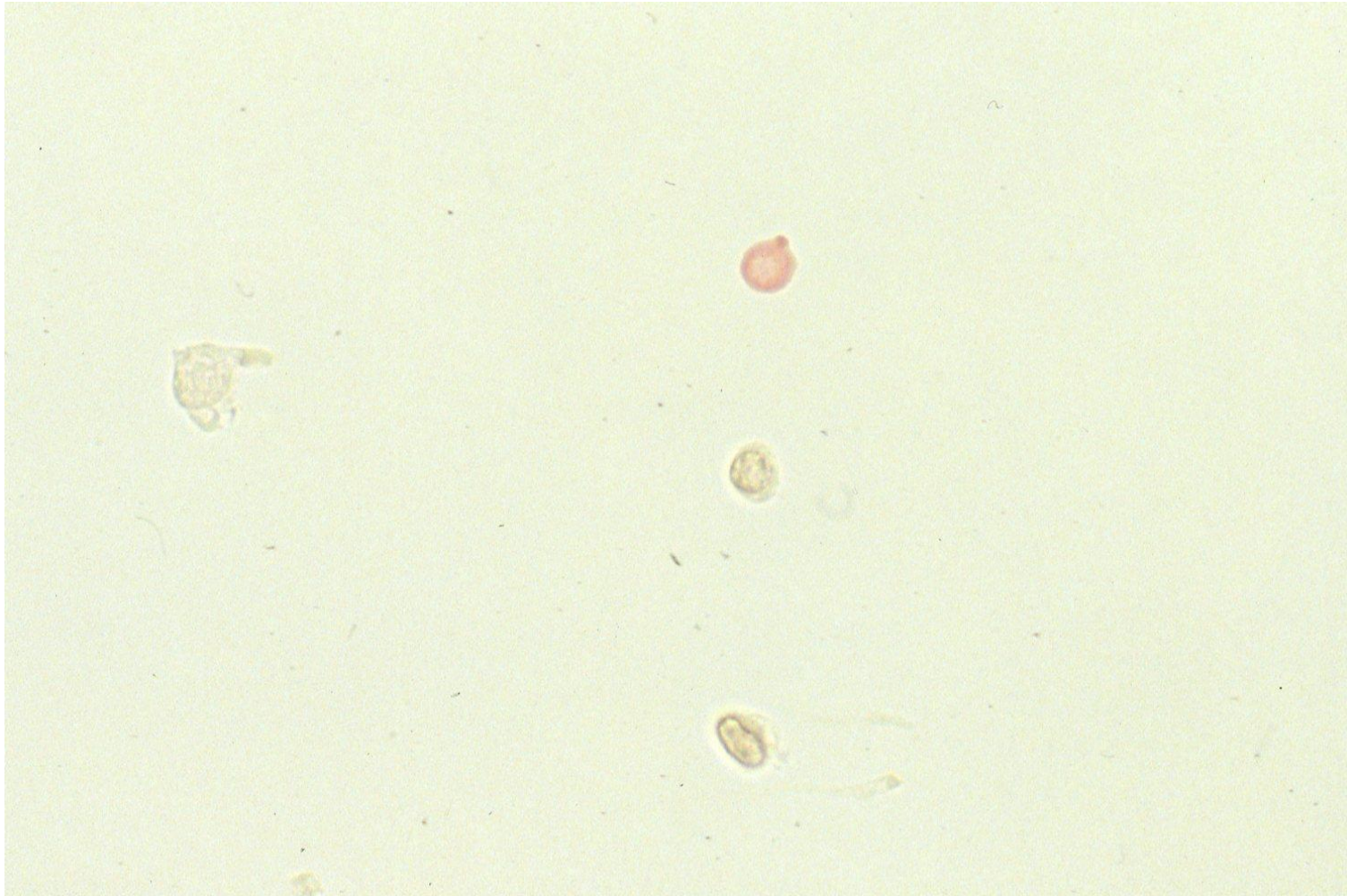
Papanicolaou-stained CSF cytology for cryptococcal meningitis.
A single yeast attaches onto the meningotheelial cell. Pap-2



Papanicolaou-stained CSF cytology for cryptococcal meningitis.
A single yeast is phagocytized by a macrophage. Pap-3



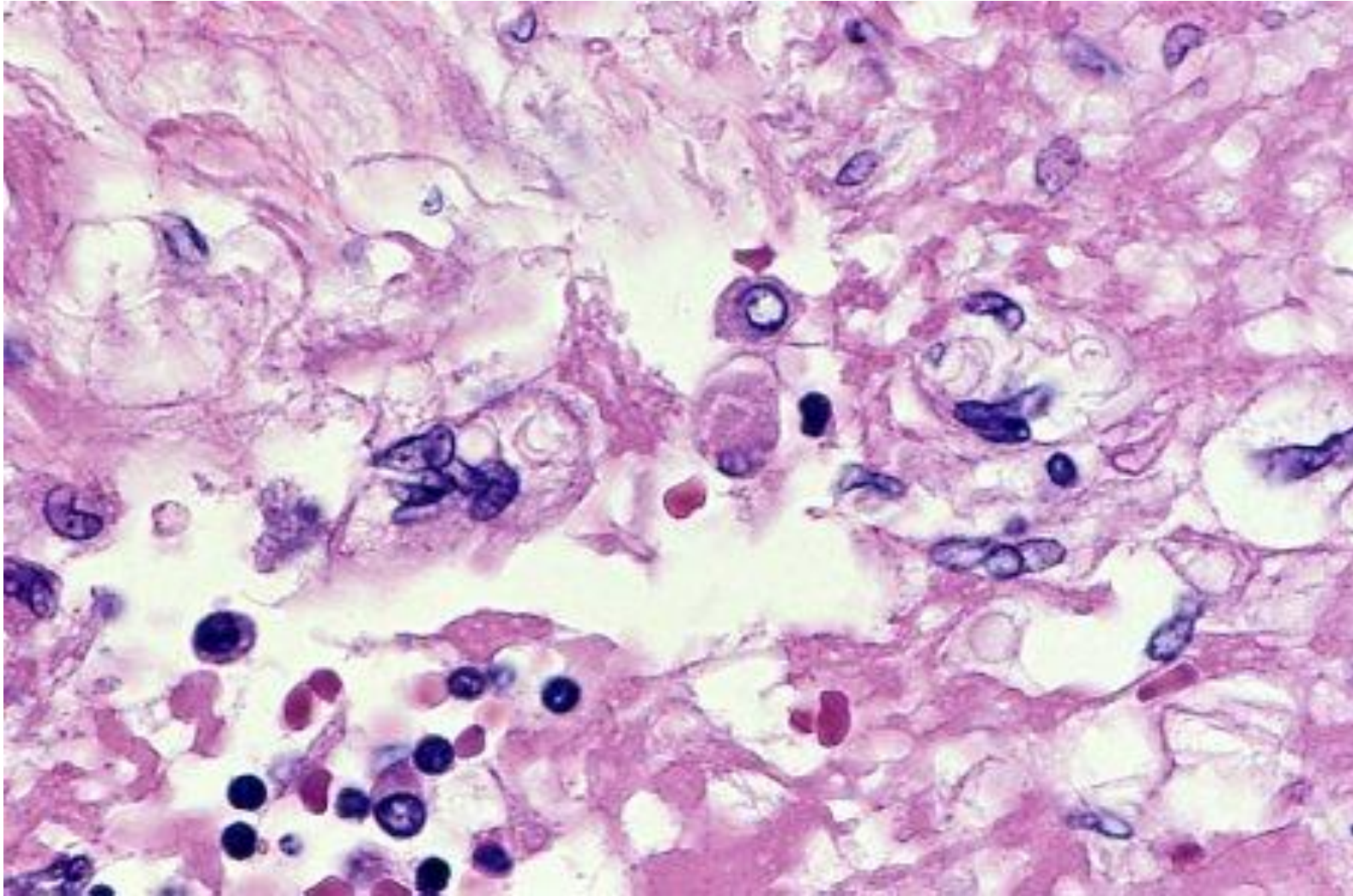
Giemsa-stained CSF cytology for cryptococcal meningitis. Poorly stained yeasts are clustered. Of note that Giemsa staining may retain more pathogens than pap staining. Giemsa



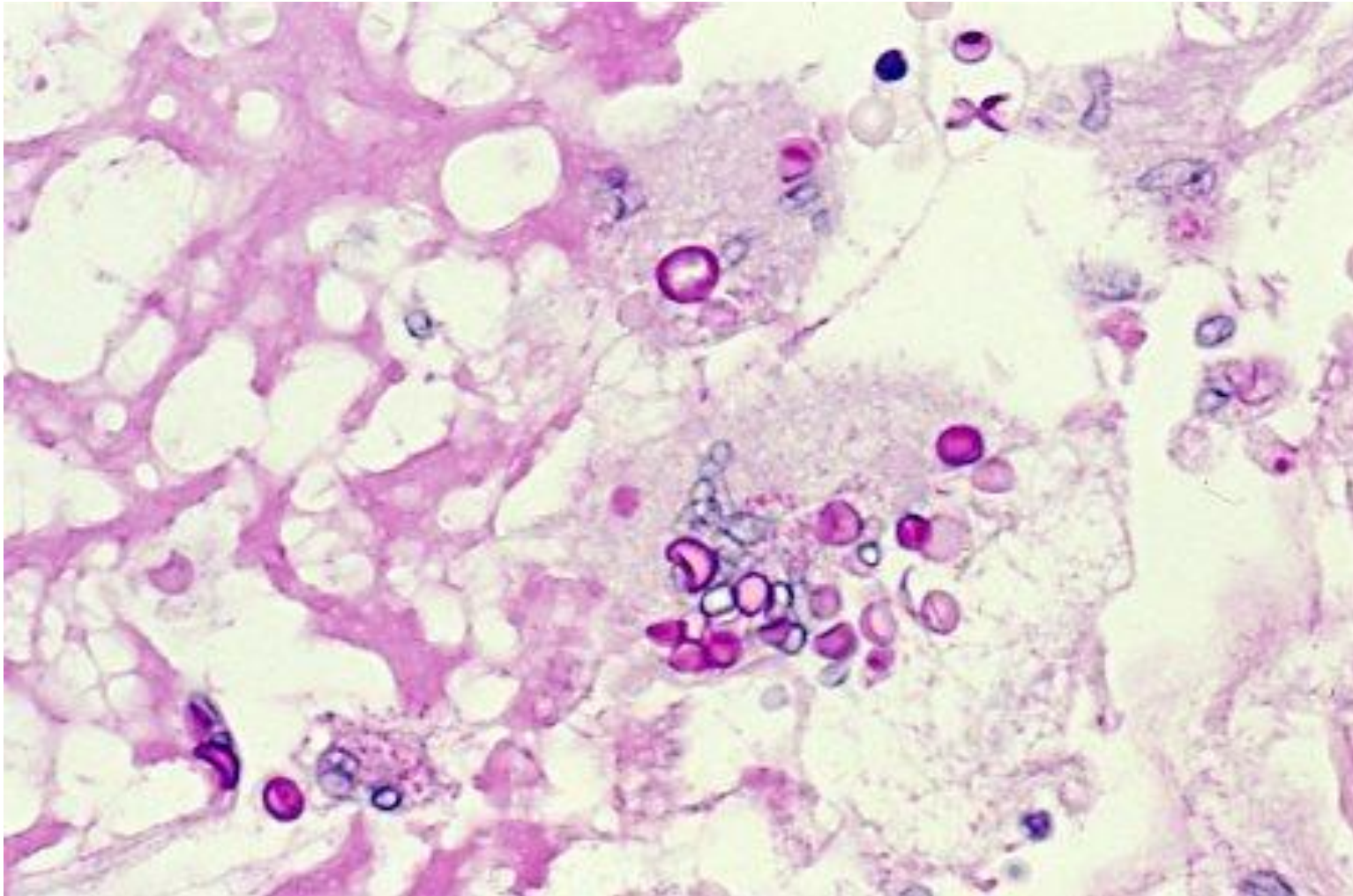
PAS-stained CSF cytology for cryptococcal meningitis. A single yeast is weakly stained with PAS reaction. PAS



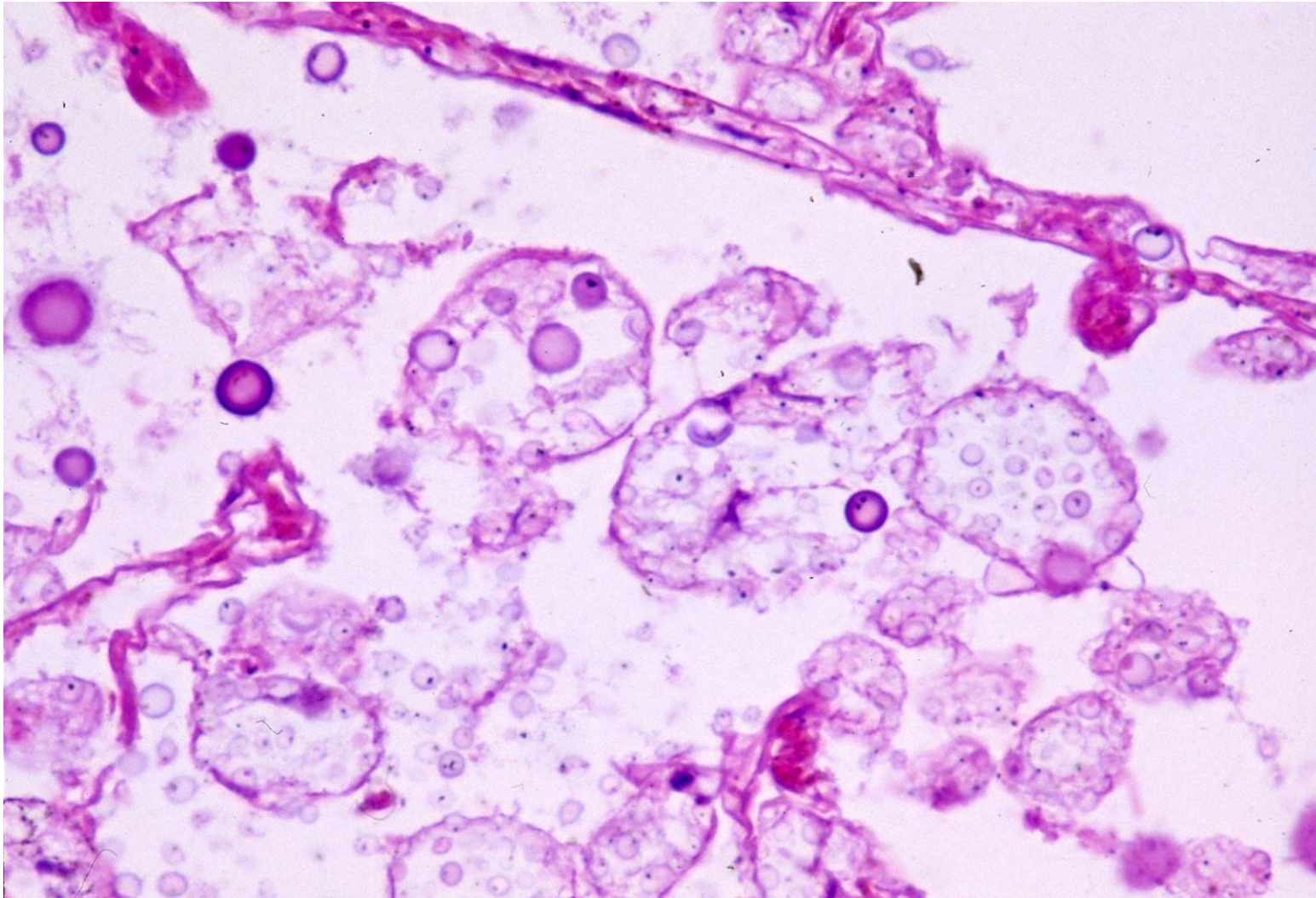
Indian ink test clearly identify yeasts in the CSF in cryptococcal meningitis. Thick capsule formation is evident. Indian ink staining



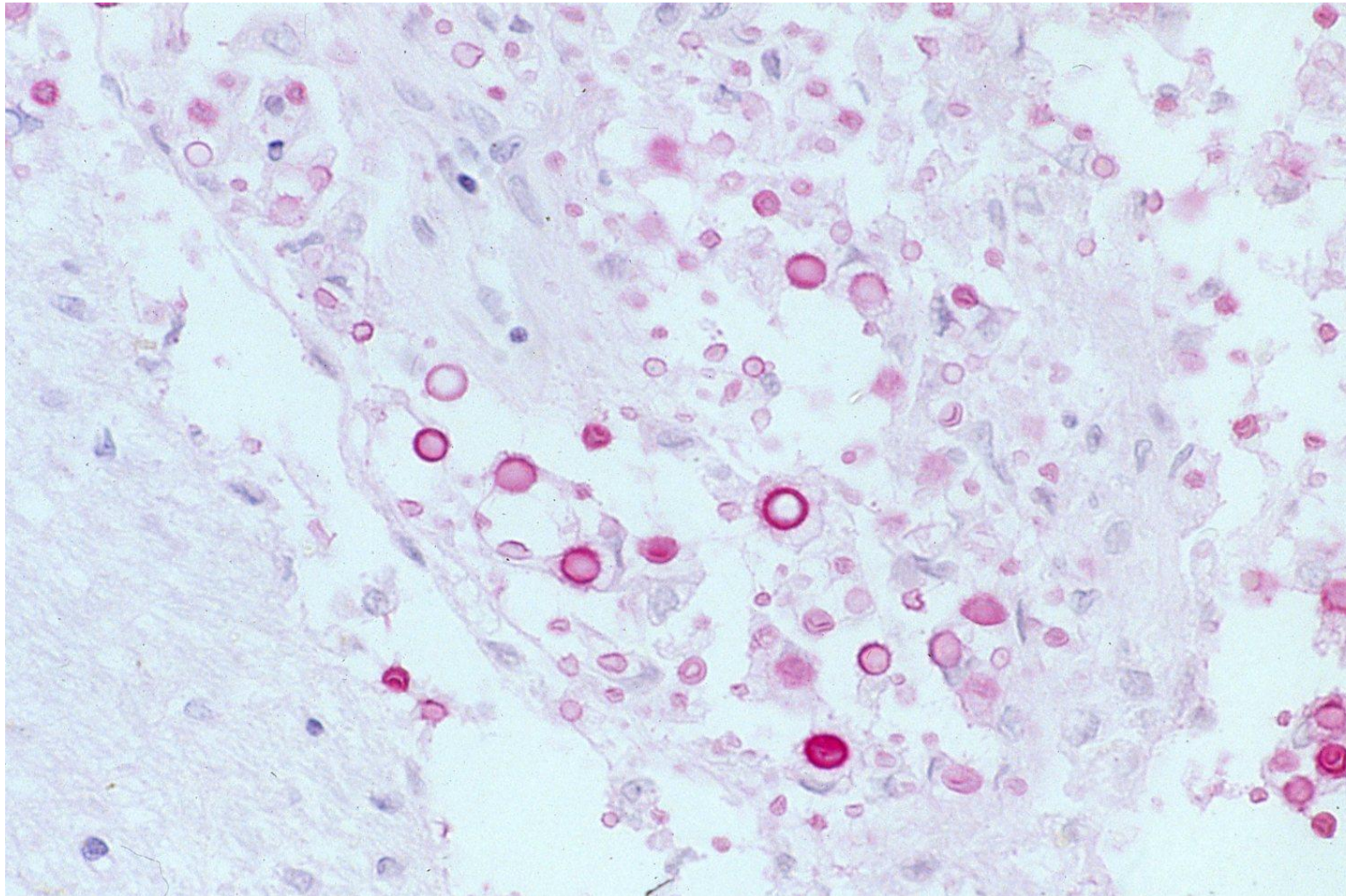
Histology of cryptococcal meningitis. Small translucent yeasts are phagocytized by macrophages in the meningeal space. H&E-1



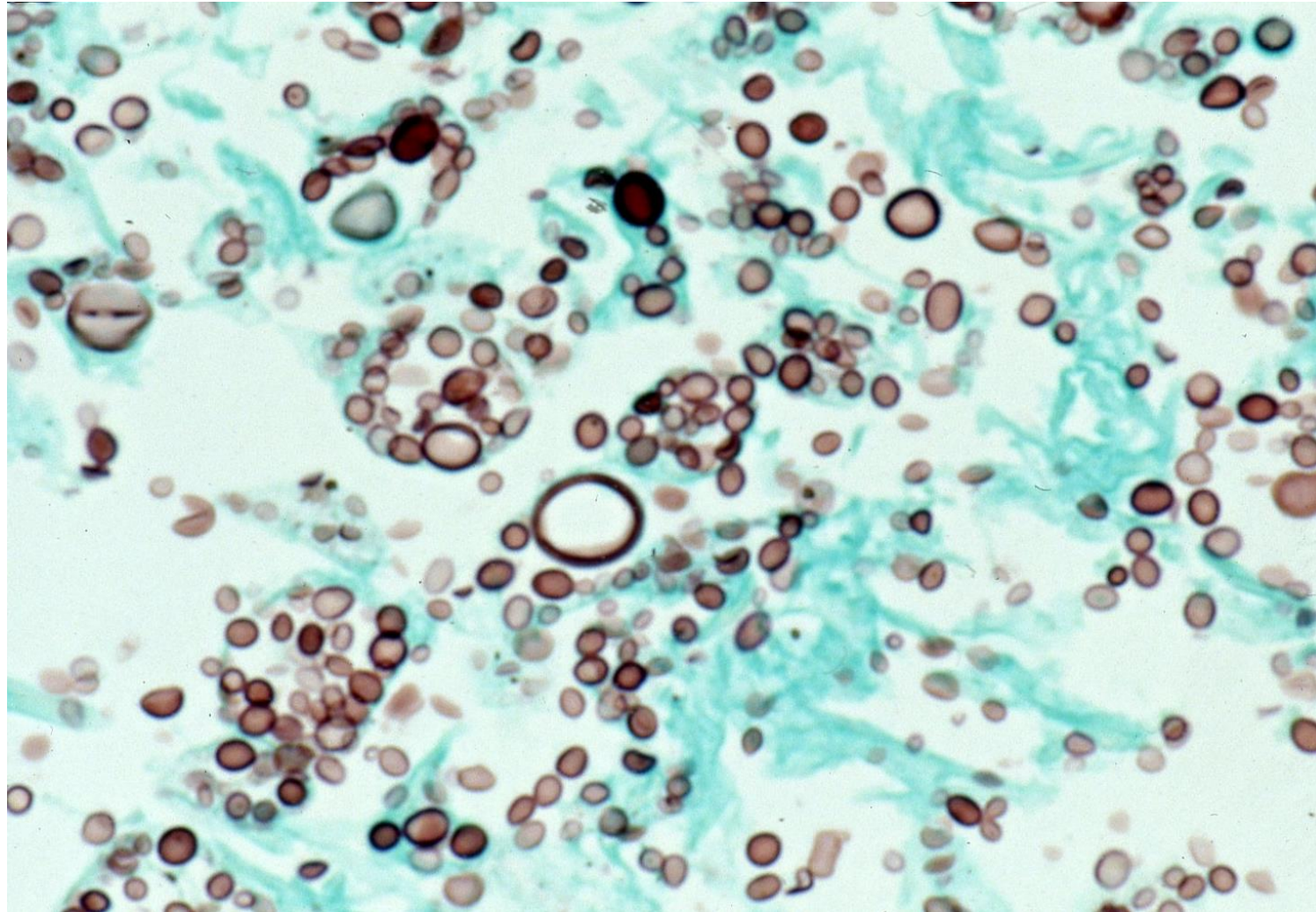
Histology of cryptococcal meningitis. Small PAS-positive yeasts are actively phagocytized by macrophages in the meningeal space. H&E-1



Histology of cryptococcal meningitis in another immunosuppressed patient. Small translucent yeasts are actively phagocytized by macrophages in the meningeal space. H&E-2



Histology of cryptococcal meningitis in another immunosuppressed patient. Mucicarmine-positive yeasts are actively phagocytized by macrophages in the meningeal space. The capsule is reactive with mucicarmine. Mucicarmine



Histology of cryptococcal meningitis in another immunosuppressed patient. Grocott-positive yeasts are actively phagocytized by macrophages in the meningeal space. The capsule is reactive with Grocott methenamine silver. Grocott